

ABM Clinical Protocol #30: Breast Masses, Breast Complaints, and Diagnostic Breast Imaging in the Lactating Woman

Katrina B. Mitchell,¹ Helen M. Johnson,² Anne Eglash,³ and the Academy of Breastfeeding Medicine

A central goal of The Academy of Breastfeeding Medicine is the development of clinical protocols, free from commercial interest or influence, for managing common medical problems that may impact breastfeeding success. These protocols serve only as guidelines for the care of breastfeeding mothers and infants and do not delineate an exclusive course of treatment or serve as standards of medical care. Variations in treatment may be appropriate according to the needs of an individual patient.

Introduction

BREASTFEEDING WOMEN MAY develop breast masses or complaints at any point during lactation. Symptoms may be related to lactation, such as a lactating adenoma, or may be due to a condition that coincidentally has manifested during the postpartum period. Understanding the importance of appropriate workup and imaging, as well as indications for referral to breast surgery, is essential to establishing a diagnosis and avoiding delay in care.

Breast symptoms require evaluation by physicians and/or lactation consultants and may also require diagnostic breast imaging and/or biopsy. The American College of Radiology (ACR) released new guidelines in 2018 regarding breast imaging of pregnant and lactating women.¹ These guidelines state that all breast imaging studies and biopsies are safe for women to undergo while breastfeeding, and also provide recommendations for maximizing examination sensitivity and minimizing biopsy-related complications in this patient population.

When approaching a breastfeeding woman with breast symptomatology, it is helpful for providers to frame the workup based on the presence or absence of a palpable mass on examination (Fig 1). Some conditions always present as a mass, whereas others rarely have a palpable finding. However, several conditions have variable presentations and may manifest as a mass and/or another sign/symptom such as nipple discharge (Fig. 2).

Quality of evidence is based on the Oxford Centre for Evidence-Based Medicine 2011 Levels of Evidence² (levels I–IV) and is noted in parentheses.

Breast Masses

The majority of persistent breast masses warrant diagnostic imaging. Although several breast masses may occur

in the setting of lactation and are benign, imaging generally is required to distinguish these from non-lactation-specific breast masses. Both benign and malignant masses unrelated to lactation also may present during the postpartum period. Thus, clinicians should perform axillary and supraclavicular lymph node examinations on all women presenting with a breast mass. Specific masses and/or associated symptomatology may warrant referral to a breast surgeon for biopsy or intervention. The most common breast masses diagnosed during lactation are highlighted in Table 1.

Lactation-specific masses

When history and examination by an experienced breastfeeding medicine physician are consistent with a lactation-related condition that the provider is comfortable managing, imaging can be deferred. If the condition presents atypically or does not resolve with standard treatment, diagnostic imaging is indicated. Examples of such conditions include the following:

- **Accessory breast tissue** occurs in 2–6% of women, most commonly in the axilla, with bilaterality in about one-third of cases. Although this tissue is congenital, women may not notice its presence until they experience physiologic breast growth during pregnancy and lactation³ (IV). Women may describe fullness during pregnancy and engorgement, and the tissue may be irritating while wearing a bra. If engorgement of this tissue does not resolve after several weeks postpartum, diagnostic imaging is indicated to rule out an alternative diagnosis.
- **Plugged ducts** occur in areas of milk stasis usually localized to a specific quadrant of the breast and resulting from milk that has remained unemptied. Plugs generally are self-limited and resolve with conservative measures such as increasing feeding frequency and gentle

¹Breast Surgical Oncology, Presbyterian Healthcare Services-MD Anderson Cancer Network, Albuquerque, New Mexico.

²Department of Surgery, Brody School of Medicine, East Carolina University, Greenville, North Carolina.

³Department of Family and Community Medicine, University of Wisconsin School of Medicine and Public Health, Madison, Wisconsin.

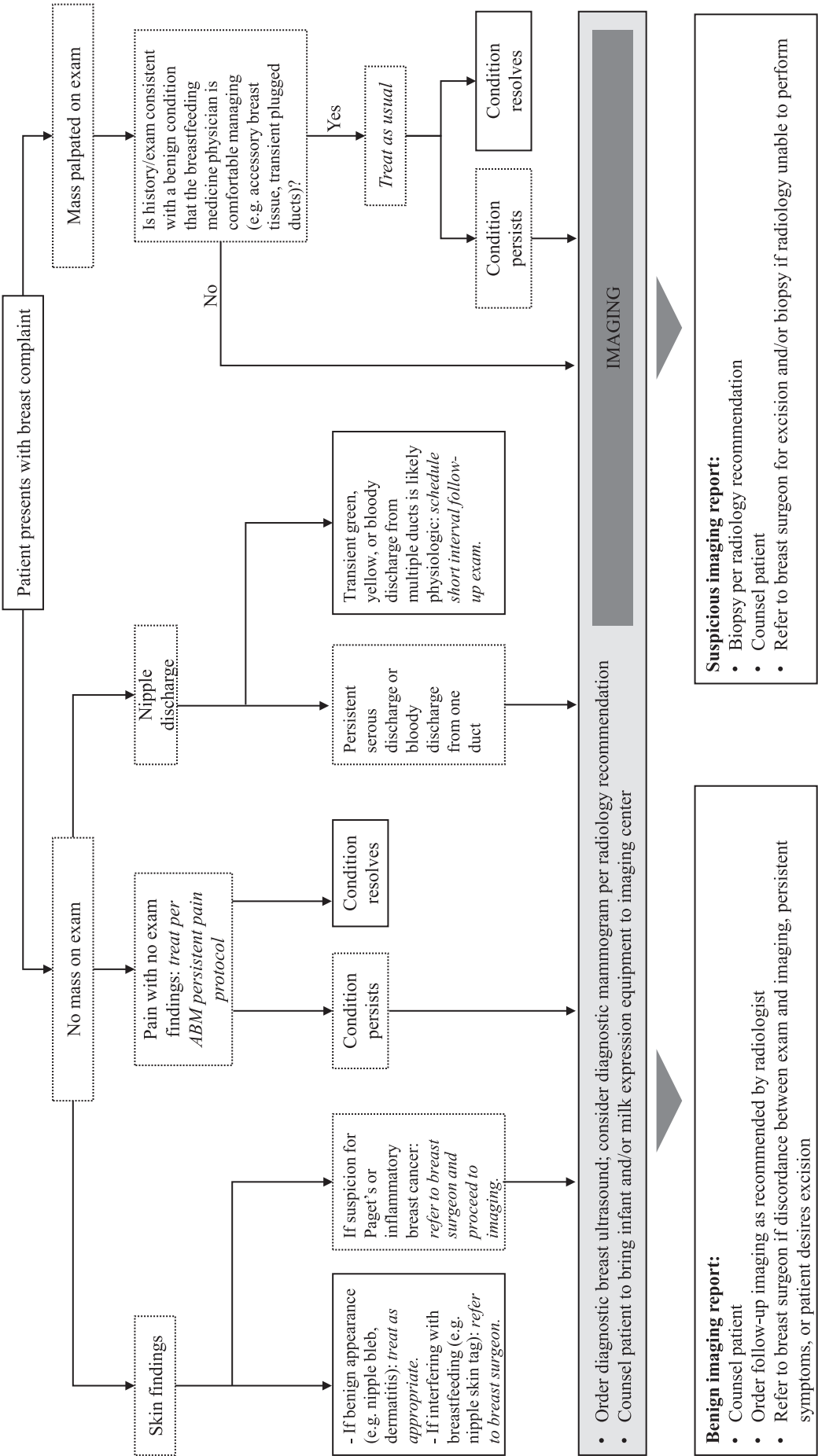


FIG. 1. Suggested approach for the evaluation of breast complaints in lactating women.

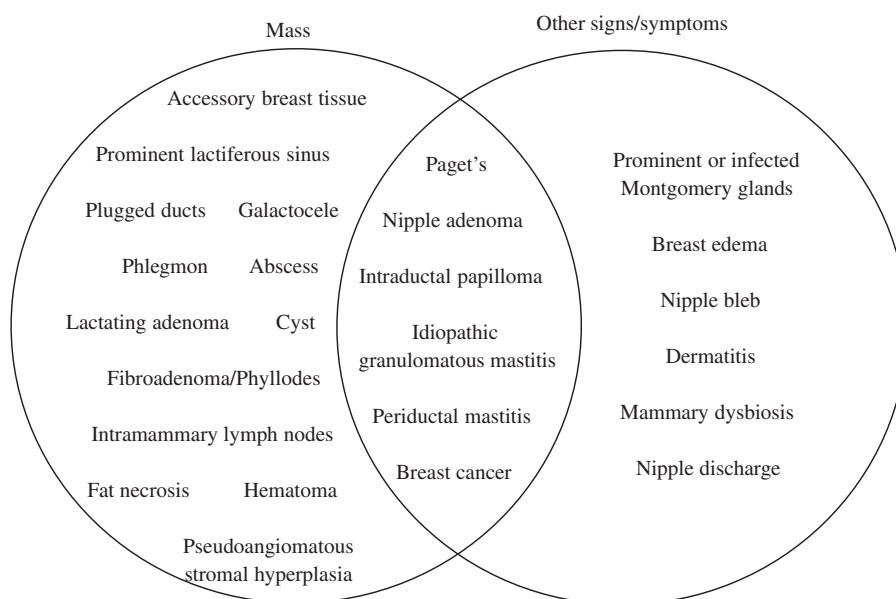


FIG. 2. Presenting signs/symptoms of common breast conditions that may affect lactating women.

massage⁴ (IV). Recurrent or persistent plugging in a ductal distribution that does not resolve with conservative measures is an indication for diagnostic imaging.

Lactation-specific masses that require imaging for diagnosis include the following:

- **Galactocele**, also known as a milk retention cyst, results from a persistent plugged duct. Galactocele is the most common benign breast mass in lactating women⁵ (IV). Large galactoceles may require referral to a breast surgeon for serial aspirations for symptomatic control. In addition, galactoceles are at risk for infection due to stasis and may warrant intervention such as drainage⁶ (IV).
- **Phlegmon**, a poorly defined fluid collection that results from obstruction and inflammation with or without infection, is well described in the surgical literature on perforated appendicitis and diverticulitis. A similar inflammatory phenomenon occurs in the lactating breast and may present as a tender mass in a ductal distribution, often associated with a recent or concurrent history of mastitis. It may have an irregular, heterogeneous, and vascular appearance on imaging and, therefore, may warrant biopsy to rule out malignancy⁷ (IV).
- **Abscess** is a well-defined fluid collection that progresses from unresolved mastitis in ~3% of cases⁸ (II). A galactocele also may undergo conversion to an infected galactocele, and a phlegmon may develop into a drainable fluid collection. Treatment options include antibiotics, aspiration, and catheter drainage. Surgical drainage no longer represents first-line treatment^{9,10} (IV, I).
- **Lactating adenomas** are painless benign masses that often present in the upper outer quadrant of breast tissue in pregnant and lactating patients, and likely are a result of hormonal stimulation. They can grow large quickly, and involute spontaneously with cessation of lactation¹¹ (IV). Biopsy is recommended to establish the diagnosis.
- **Lactiferous sinuses** may be more prominent in breast-feeding women and present as a subareolar mass¹² (IV).

Non-lactation-specific masses

Benign masses that are not specific to lactation include the following:

- **Fibroadenoma**, the most common benign breast mass to present in the reproductive years, is highlighted in Table 1.
- **Phyllodes tumor**, a fibroepithelial lesion similar to a fibroadenoma, has the potential for malignant transformation. Any suspicion of phyllodes requires surgical excision to rule out malignancy¹³ (IV).
- **Cysts** are particularly common in women with fibrocystic breasts and are readily classified as simple or complex by ultrasonography. Complex cysts require aspiration for cytologic analysis, whereas simple cysts can be observed¹⁴ (IV).
- **Pseudoangiomatous stromal hyperplasia** is a benign, often irregular, firm mobile mass that can grow large but does not require surgical excision if proven on biopsy¹⁵ (IV).
- **Intramammary lymph nodes**, although uncommon to palpate, are sometimes discovered by patients. Imaging can distinguish between benign versus malignant appearance¹⁶ (I).
- **Fat necrosis** is common after previous breast surgery or trauma; although benign, this condition may present as an irregular palpable mass that may be tender or asymptomatic¹⁷ (IV).
- **Hematoma** can also develop after trauma, such as a motor vehicle accident involving seat belt injury, or vigorous massage in the setting of lactation¹⁸ (IV). In addition to a mass, transient nipple discharge may occur.
- **Periductal mastitis** is an uncommon condition that generally presents in smokers and results from squamous metaplasia of the lactiferous ducts. Patients experience chronic, persistent abscesses, and fistulae in the superficial periareolar region. Optimal treatment is

TABLE 1. MOST COMMON BREAST MASSES DIAGNOSED DURING LACTATION

<i>Condition</i>	<i>Clinical presentation</i>	<i>Diagnostic considerations</i>	<i>Treatment options</i>
Lactating adenoma	Painless rubbery mobile mass. Often in upper outer quadrant. Grows rapidly due to hormonal stimulation.	Core needle biopsy recommended to establish diagnosis	Observation (mass spontaneously regresses after weaning)
Galactocele	Painless lump, may be single or multiple, unilateral or bilateral. Somewhat more common in the retroareolar region.	Aspiration of milky fluid can confirm the diagnosis. At risk for infection due to milk stasis, so may mimic abscess.	Observation (mass spontaneously resolves) versus serial aspirations and or/drainage catheter for symptomatic control
Phlegmon	Tender persistent mass in ductal distribution	May or may not have antecedent and/or concomitant infectious symptoms (e.g., erythema)	Conservative measures (e.g., ice), antibiotic therapy, and surveillance to monitor for progression to abscess
Abscess	Fluctuant tender mass with overlying erythema and induration	Aspiration or drainage of purulent material can confirm the diagnosis	Drainage +/- antibiotic therapy
Fibroadenoma	Rubbery smooth mobile mass. More common in upper outer quadrant. May be asymptomatic or tender. Growth during pregnancy and/or lactation.	Core needle biopsy is recommended for lesions >2–3 cm to rule out Phyllodes tumor, significant growth rate, and/or discordance between clinical and radiographic findings	Surveillance versus surgical excision for symptomatic control
Breast cancer	Variable. May be occult, present as a mass (usually nontender), present as skin/soft tissue changes such as dimpling or nipple retraction, or present with spontaneous bloody or serous nipple discharge.	Core needle biopsy, image guided in the case of nonpalpable cancers, is required for diagnosis and treatment selection. In the case of an equivocal percutaneous biopsy, surgical biopsy may be required.	Treatment varies according to stage and tumor characteristics such as histologic subtype and hormonal receptor expression

controversial and may include smoking cessation, antibiotic therapy, and/or drainage, with surgical excision reserved for refractory cases¹⁹ (IV).

- **Idiopathic granulomatous mastitis** is an inflammatory disorder of the breast with unclear etiology that results in erythema, abscess, and fistula formation. It most often occurs in young women of Hispanic descent within several years of pregnancy or lactation²⁰ (IV). The presentation is variable and can mimic other conditions such as bacterial mastitis or inflammatory breast cancer. Diagnosis is made by exclusion, including negative cultures to rule out infectious mastitis and biopsy to rule out malignancy and to confirm histopathologic evidence of noncaseating granulomas.

Breast cancer (Table 1) is the most commonly diagnosed malignancy among women in their reproductive years and thus may present during lactation. In addition, breastfeeding women are at risk for postpartum breast cancer, which has higher risk of metastatic spread than other forms of breast cancer. Women with postpartum breast cancer have markedly lower 5-year overall survival when compared with nulliparous cases, even adjusting for biologic subtype and stage at diagnosis²¹ (III). Breast cancer is a broad term that includes pre-invasive disease and invasive disease. Diagnosis is established histologically. Management is multidisciplinary in nature and is complex, tailored to the individual patient.

Non-Mass Breast Complaints

Breastfeeding women seeking medical evaluation of breast symptoms who do not have a palpable mass on examination may present with a variety of conditions, some of which require diagnostic imaging. These conditions can be categorized into skin conditions, nipple discharge, and breast pain.

Skin conditions

A number of skin conditions can be diagnosed by history and physical examination and thus do not require diagnostic imaging. Benign lesions that are interfering with breastfeeding, such as a skin tag on the nipple–areolar complex (NAC), warrant referral to a breast surgeon. Lesions that raise suspicion for Paget’s disease, inflammatory breast cancer, or other malignancy require both diagnostic imaging and referral to a breast surgeon.

Examples of skin conditions for which breastfeeding women may seek care include the following:

- **Montgomery glands** serve to lubricate the areola and nipple and attract the infant to the breast through olfactory signals. They naturally enlarge during lactation and pregnancy and may not have been noticeable before this time²² (IV). They may become obstructed and/or infected like any other sebaceous gland and

require treatment with warm compresses and/or topical antibiotics.

- **Breast edema** is common in women with larger breasts. It may become more pronounced during pregnancy and lactation, particularly in the immediate postpartum period associated with engorgement. Reassuring features include bilaterality, edema confined only to the dependent portion of the breast, and improvement with supportive bras. If the patient or provider is concerned, referral can be made for diagnostic imaging and breast surgery evaluation.
- **Nipple bleb** an inflammatory lesion of the surface of one or multiple nipple orifices is often white or yellow. Blebs can cause significant latch pain and/or ductal obstruction despite their small size. They may resolve spontaneously. Management for more tenacious blebs includes warm compresses, steroid cream, or procedural unroofing²³ (IV). If persistent and/or causing plugging and mass-like obstruction, imaging may be warranted in certain patients.
- **Dermatitis** may be localized to the NAC or involves the skin of the breast. The risk of dermatitis may be increased in a breastfeeding patient with a history of atopy and allergy: the mother may have an allergy to ingredients in nipple creams such as lanolin, or allergic to substances the child is touching or ingesting²⁴ (IV).
- **Subacute mastitis, or mammary dysbiosis**, also may cause nipple flaking, erythema, blebs, and scabbing of the nipple and areola with associated deep breast pain. This condition has been termed “mammary candidiasis” in this past, but newer research is disproving the causative agent as yeast and implicating bacterial imbalance instead²⁵ (IV).
- **Paget’s disease** is an eczematous oozing itching lesion of the NAC usually associated with underlying breast malignancy. It arises on the nipple and progresses to the areola; this develops in contrast to dermatitis, which generally behaves oppositely. If Paget’s disease is suspected, referral to a breast surgeon for punch biopsy and diagnostic imaging is required²⁶ (III).
- **Nipple adenoma**, also known as erosive adenomatosis of the nipple, nipple papillomatosis, or papillary adenoma of the nipple, presents with a nipple nodule, nipple erosion, and/or nipple discharge and can mimic Paget’s disease. Nipple adenomas are benign lesions, although they may be associated with preinvasive or invasive lesions²⁷ (IV).

Nipple discharge

Although breastfeeding women experience physiologic milk expression from their nipple orifices, they also may note other colors of **nipple discharge** during lactation. Bilateral multiduct discharge that is yellow or green is generally not concerning and considered physiologic²⁸ (IV). Serous nipple discharge is more concerning for malignancy and should be evaluated with diagnostic imaging.

Bloody discharge may be due to several conditions including the following:

- **“Rusty pipe syndrome”** is the term for transient bilateral multiduct rusty brown or bloody discharge seen

in the first few weeks of lactation that resolves spontaneously²⁹ (IV).

- In addition, bloody nipple discharge may occur in up to 24% of women at any point during lactation³⁰ (IV). This phenomenon is related to proliferative epithelial changes and increased vascularity in the breast, and is usually self-limited. Persistent bloody nipple discharge presenting after the immediate postpartum period should be evaluated with diagnostic imaging.
- **Papillary** lesions of the breast, which represent a spectrum of disease from benign **intraductal papilloma** to **papillary carcinoma**, often present with bloody nipple discharge. Persistent unilateral bloody nipple discharge, particularly from a single duct and/or if associated with a subareolar mass, warrants imaging³¹ (IV).
- Although pink- or red-tinged expressed milk may raise concern for bloody nipple discharge, this phenomenon may be due to colonization with the pigment-producing bacterium *Serratia marcescens* and should resolve with antibiotic therapy³² (IV).

Breast pain

The workup and treatment for breast pain in lactating women with no mass or other physical examination findings to suggest a diagnosis have been previously described and are beyond the scope of this protocol³³ (IV). Women with pain that does not resolve with appropriate intervention should undergo diagnostic imaging.

Diagnostic Breast Imaging and Breast Biopsy During Lactation

Few international organizations report specific recommendations regarding breast imaging during lactation. The ACR recommends that diagnostic breast imaging in lactating women follow the same guidelines as for nonlactating women¹ (IV), with the exception of ductography that is not recommended in lactation³⁴ (IV). As shown in Figure 1, we recommend diagnostic breast imaging of almost all breast masses and for several specific non-mass breast complaints.

For diagnostic imaging in a breastfeeding woman, ultrasonography is recommended as the initial imaging modality. If ultrasonography shows suspicious findings or is discordant with clinical examination, additional imaging with mammography or digital breast tomosynthesis (DBT, or “3D mammography”) may be indicated.¹ This is related to the fact that mammogram or DBT can visualize architectural distortion and/or calcifications not seen on ultrasonography, as well as delineate extent of disease in the setting of malignancy³⁵ (IV).

Core needle biopsy rather than fine needle aspiration should be performed after a full diagnostic imaging workup has been completed. Core needle biopsy generally can be performed under ultrasound guidance for a palpable mass. However, if the mass does not have an ultrasound correlate, a woman may be recommended to undergo a stereotactic core needle biopsy with mammographic guidance or a magnetic resonance imaging (MRI)-guided biopsy. Although there is a small but rare risk of milk fistula, this risk should not preclude biopsy of any suspicious lesion³⁶ (IV). Lactating women should also be counseled about a theoretical small

increased risk of postprocedural bleeding secondary to hypervascularity³⁷ (IV). We do not recommend discontinuation of breastfeeding before biopsy in an effort to minimize these risks. In fact, the inflammation related to abrupt weaning³⁸ (IV) could increase the risk of fistula formation, and lack of alternative drainage routes (e.g., through the nipple) could promote fistula formation through the biopsy tract.

If a woman is diagnosed with a breast malignancy on initial imaging and biopsy, she may be recommended to undergo additional biopsy of suspicious lymph nodes in her regional nodal basins (axillary, internal mammary, and supra- and infraclavicular). Breast radiology and breast surgical oncology also may recommend breast MRI to rule out multifocal or multicentric tumors, contralateral disease, or pectoralis and/or skin involvement. Although MRI is less sensitive in the setting of lactation due to increased parenchymal density and vascularity, it nevertheless is not contraindicated and may provide diagnostic and treatment planning benefit.¹

Recommendations for Future Research

Although there is strong evidence for the safety and feasibility of nearly all breast imaging studies in lactating women, the data on the relative sensitivities of each modality are limited. There is a growing body of literature that describes normal imaging findings in the lactating breast compared with the nonlactating breast, but there is a paucity of data on the radiologic differences between lactating women with specific pathologies and lactating women without breast lesions. Another area for further study is the management of breast masses and breast complaints of transgender individuals who are chestfeeding. In the absence of specific data, it is reasonable to follow the algorithms described herein for lactating women.

References

- Expert Panel on Breast Imaging: diFlorio-Alexander RM, Slanetz PJ, Moy L, et al. ACR Appropriateness Criteria® Breast imaging of pregnant and lactating women. *J Am Coll Radiol* 2018;15:S263–S275.
- OCEBM Levels of Evidence Working Group. The Oxford 2011 Levels of Evidence. Oxford Centre for Evidence-Based Medicine. Available at <http://www.cebm.net/index.aspx?o=5653> (accessed January 30, 2019).
- Lesavoy MA, Gomez-Garcia A, Nejdil R, et al. Axillary breast tissue: Clinical presentation and surgical treatment. *Ann Plast Surg* 1995;35:356–360.
- World Health Organization. Mastitis: Causes and management. 2000. Available at http://apps.who.int/iris/bitstream/handle/10665/66230/WHO_FCH_CAH_00.13_eng.pdf?sequence=1 (accessed January 30, 2019).
- Couto LS, Glassman LM, Batista Abreu DC, et al. Chronic galactoceles. *Breast J* 2016;22:471–472.
- Ghosh K, Morton MJ, Whaley DH, et al. Infected galactocoele: A perplexing problem. *Breast J* 2004;10:159.
- Johnson HM, Mitchell KB. Lactational phlegmon: a distinct clinical entity within the mastitis-abscess spectrum. Accepted for presentation at the American Society of Breast Surgeon's 20th Annual Meeting on May 4, 2019, in Dallas, TX. *Ann Surg Oncol* (in press).
- Amir LH, Forster D, McLachlan H, et al. Incidence of breast abscess in lactating women: Report from an Australian cohort. *BJOG* 2004;111:1378–1381.
- Amir LH; the Academy of Breastfeeding Medicine. ABM Clinical Protocol #4: Mastitis, revised March 2014. *Breastfeed Med* 2014;9:239–243.
- Irusen H, Rohwer AC, Steyn DW, et al. Treatments for breast abscess in breastfeeding women. *Cochrane Database Syst Rev* 2015;17:CD010490.
- Barco Nebreda I, Vidal MC, Fraile M, et al. Lactating adenoma of the breast. *J Hum Lact* 2016;32:559–562.
- Nicholson BT, Harvey JA, Cohen MA. Nipple-areolar complex: Normal anatomy and benign and malignant processes. *Radiographics* 2009;29:509–523.
- Tan BY, Acs G, Apple SK, et al. Phyllodes tumours of the breast: A consensus review. *Histopathology* 2016;68:5–21.
- Langer A, Mohallem M, Berment H, et al. Breast lumps in pregnant women. *Diagn Interv Imaging* 2015;96:1077–1087.
- Virk RK, Khan A. Pseudoangiomatous stromal hyperplasia: An overview. *Arch Pathol Lab Med* 2010;134:1070–1074.
- Abdulgaffar B, Gopal P, Abdulrahim M, et al. The significance of intramammary lymph nodes in breast cancer: A systematic review and meta-analysis. *Int J Surg Pathol* 2012;20:555–563.
- Tan PH, Lai LM, Carrington EV, et al. Fat necrosis of the breast—A review. *Breast* 2006;15:313–318.
- Madden B, Phadtare M, Ayoub Z, et al. Hemorrhagic shock from breast blunt trauma. *Int J Emerg Med* 2015;8:83.
- Taffurelli M, Pellegrini A, Santini D, et al. Recurrent periductal mastitis: Surgical treatment. *Surgery* 2016;160:1689–1692.
- Barreto DS, Sedgwick EL, Nagi CS, et al. Granulomatous mastitis: Etiology, imaging, pathology, treatment, and clinical findings. *Breast Cancer Res Treat* 2018;171:527–534.
- Callihan EB, Gao D, Jindal S, et al. Postpartum diagnosis demonstrates a high risk for metastasis and merits and expanded definition of pregnancy-associated breast cancer. *Breast Cancer Res Treat* 2013;138:549–559.
- Doucet S, Soussignan R, Sagot P, et al. The secretion of areolar (Montgomery's) glands from lactating women elicits selective, unconditional responses in neonates. *PLoS One* 2009;4:37579.
- Tait P. Nipple pain in breastfeeding women: Causes, treatment, and prevention strategies. *J Midwifery Womens Health* 2000;45:212–215.
- Barrett ME, Heller MM, Fullerton Stone H, et al. Dermatoses of the breast in lactation. *Dermatol Ther* 2013;26:331–336.
- Eglash A, Plane MB, Mundt M. History, physical and laboratory findings, and clinical outcomes of lactating women treated with antibiotics for chronic breast and/or nipple pain. *J Hum Lact* 2006;22:429–433.
- Kothari AS, Beechey-Newman N, Hamed H, et al. Paget disease of the nipple: A multifocal manifestation of higher-risk disease. *Cancer* 2002;95:1–7.
- Lee C, Boughey J. Case report of a synchronous nipple adenoma and breast carcinoma with current multi-modality radiologic imaging. *Breast J* 2016;22:105–110.
- Stone K, Wheeler A. A review of anatomy, physiology, and benign pathology of the nipple. *Ann Surg Oncol* 2015;22:3236–3240.

29. Silva JR, Carvalho R, Maia C, et al. Rusty pipe syndrome, a cause of bloody nipple discharge: Case report. *Breastfeed Med* 2014;9:411–412.
30. Kline TS, Lash SR. The bleeding nipple of pregnancy and postpartum period: A cytologic and histologic study. *Acta Cytol* 1964;8:336–340.
31. de Paula IB, Campos AM. Breast imaging in patients with nipple discharge. *Radiol Bras* 2017;50:383–388.
32. Quinn L, Ailsworth M, Matthews E, et al. *Serratia marcescens* colonization causing pink breast milk and pink diapers: A case report and literature review. *Breastfeed Med* 2018;13:388–394.
33. Berens P, Eglash A, Malloy M, et al.; the Academy of Breastfeeding Medicine. ABM Clinical Protocol #26: Persistent pain with breastfeeding. *Breastfeed Med* 2016;11:46–53.
34. Expert Panel on Breast Imaging: Lee SJ, Trikha S, Moy L, et al. ACR Appropriateness Criteria® Evaluation of nipple discharge. *J Am Coll Radiol* 2017;14:S138–S153.
35. Expert Panel on Breast Imaging: Moy L, Heller SL, Bailey L, et al. ACR Appropriateness Criteria® Palpable breast masses. *J Am Coll Radiol* 2017;14:S203–S224.
36. Larson KE, Valente SA. Milk fistula: Diagnosis, prevention, and treatment. *Breast J* 2016;22:111–112.
37. Sabate JM, Clotet M, Torrubia S, et al. Radiologic evaluation of breast disorders related to pregnancy and lactation. *Radiographics* 2007;27 Suppl 1:S101–S124.
38. Silanikove N. Natural and abrupt involution of the mammary gland affects differently the metabolic and health consequences of weaning. *Life Sci* 2014;102:10–15.

ABM protocols expire 5 years from the date of publication.

Content of this protocol is up-to-date at the time of publication. Evidence-based revisions are made within 5 years or sooner if there are significant changes in the evidence.

Katrina B. Mitchell, MD, lead author
Helen M. Johnson, MD
Anne Eglash, MD

The Academy of Breastfeeding Medicine
 Protocol Committee

Michal Young, MD, Chairperson
Larry Noble, MD, Translations Chairperson
Sarah Reece-Stremtan, MD, Secretary
Melissa Bartick, MD, MSc
Sarah Calhoun, MD
Sarah Dodd, MD
Megan Elliott-Rudder, PhD, MBBS
Laura Rachel Kair, MD
Susan Lappin, MD
Ilse Larson, MD
Ruth A. Lawrence, MD
Yvonne LeFort, MD
Kathleen A. Marinelli, MD
Nicole Marshall, MD
Catherine Murak, MD
Eliza Myers, MD
Adora Okogbule-Wonodi, MD
Audrey Roberts, MD
Casey Rosen-Carole, MD, MPH, MEd
Susan Rothenberg, MD
Tricia Schmidt, MD
Tomoko Seo, MD
Natasha Sriraman, MD, MPH
Elizabeth K. Stehel, MD
Rose St. Fleur, MD
Lori Winter, MD, MPH
Gina Weissman, DMD, RN
Nancy Wight, MD

For correspondence: abm@bfmed.org